

Pseudotumor Tuberculosis of liver: a Rare Entity

Mehdi Soufi¹, Ghizlane Kharrasse², Khanoussi wafae², Zahi Ismaili², Tijani El haroudi¹, Mohammed Bouziane².

1. Department of digestive Surgery, Faculty of medicine Oujda, University Mohammed first, Oujda -Morocco
2. Department of gastroenterology, Faculty of medicine Oujda, University Mohammed first, Oujda -Morocco

Abstract

We present a rare case of a 46-year-old man who presented with recurrent fever and abdominal pain without other symptoms. Laboratory data were no specific for diagnosis. Abdominal imaging revealed a pseudotumor liver. A diagnosis of isolated liver tuberculosis with abscess component was confirmed with US-guided liver biopsy and histopathological examination. The patient received antibacillous drugs with success.

Keys words: tuberculosis, Liver, pseudotumor, antibacillous drugs.

Corresponding Author: Mehdi Soufi, MD, Division of digestive and oncological Surgery, Oujda CHU, faculty of medicine. University Mohammed first

Bp 4847 Oujda université 60049, Oujda Morocco

(Tel: +212661212924; Email: drsoufimehdi@hotmail.fr)

Running title : PTL

Received : Jul 30, 2014;

Accepted : Nov 11, 2014;

Published; Feb 12, 2015

Introduction:

Tuberculosis is one of the most common diseases in Morocco [1]. Although the prevalence of tuberculosis decreased quickly worldwide after the widespread use of antibacillous drugs, the prevalence has increased in recent years in immunocompromised and immunocompetent patients [1]. Hepatic tuberculosis is an uncommon form of extrapulmonary tuberculosis. It is usually a disseminated disease associated with military tuberculosis, which is one of the most characteristic manifestations of tuberculosis. Localized tuberculosis of the liver in the pseudotumor form is rare [2]. We report a rare case of isolated liver tuberculosis in young patient without any immunodeficiency treated successfully with antibacillous drugs.

Case Report:

A 46 year old man was admitted with 5 months history of remittent fever ranging between 37.6°C and 38.2°C. The fever was associated with chills and epigastric pain, as well as night sweats. The patient has also a history of 10 Kg weight loss along with loss of appetite. On clinical

examination, the patient was, oriented in time and space, cooperative, febrile 37,9, anicteric and normopneic, without peripheral lymphadenopathy. He had abdominal tenderness in the epigastric region, without hepatosplenomegaly.

Laboratory analysis showed hemoglobin, 10.9 g/dL; white blood cell count, 9,800 cells/mm³, serum albumin, serum total bilirubin, alanine aminotransferase, aspartate aminotransferase, prothrombin time, hepatitis B surface antigen, and antibodies to hepatitis C, serum alpha-fetoprotein (AFP), carcinoembryonic antigen and carbohydrate antigen 19-9 (CA 19-9) were within normal range. Blood cultures were negative. Chest x-ray was normal. Ultrasound of abdomen showed a 10 cm hypoechoic lesion in left liver (Figure 1). An abdominal CT showed a well-defined heterogeneous mass situated in his left hepatic lobe measuring 10 cm × 7 cm (Figure 2,3). The lesion featured central necrosis, a hyper-dense rim and a mild enrichment from the arterial phase in the CT, The diagnosis of primary hepatic tumor was suspected. An ultrasonography-guided needle

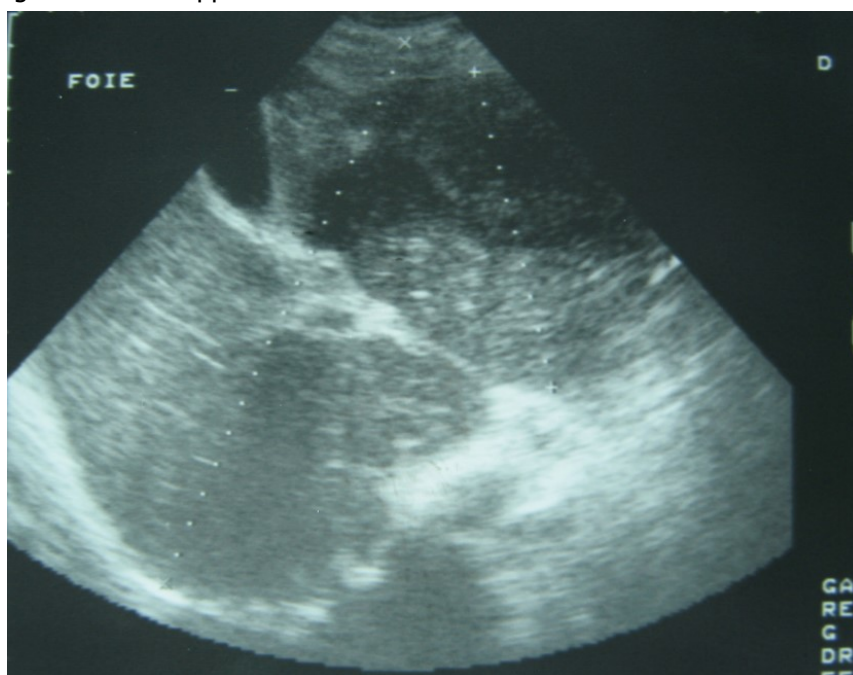


Figure 1: Ultrasonography showing a 10 cm hypoechoic lesion

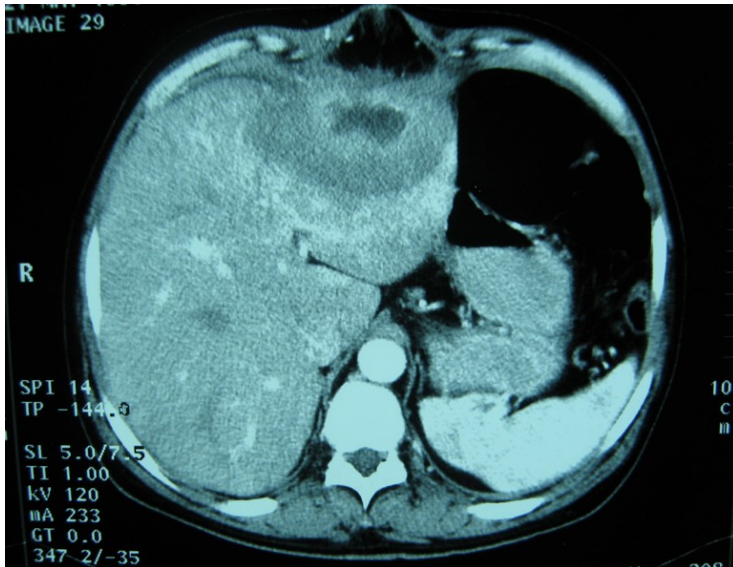


Figure 2: Abdominal computed tomography with intravenous contrast showing 10x7 cm low-density focal lesion

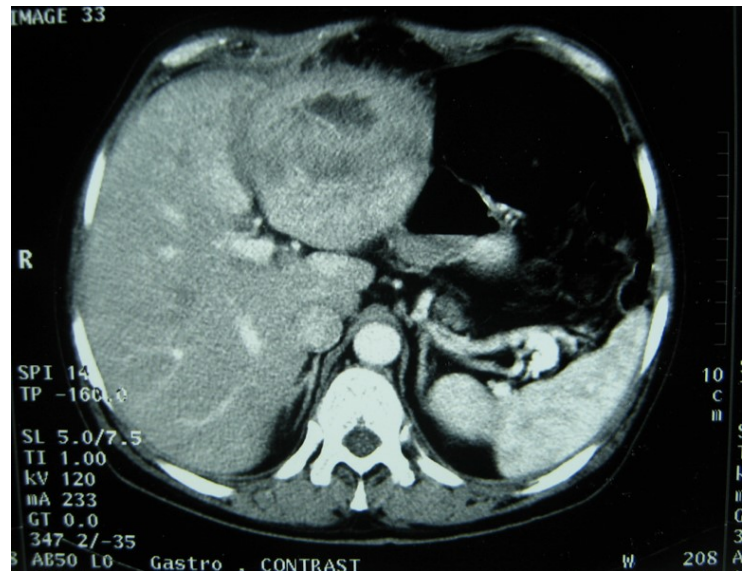

Figure 3: Abdominal computed tomography with intravenous contrast showing the lesion with ring enhancement.

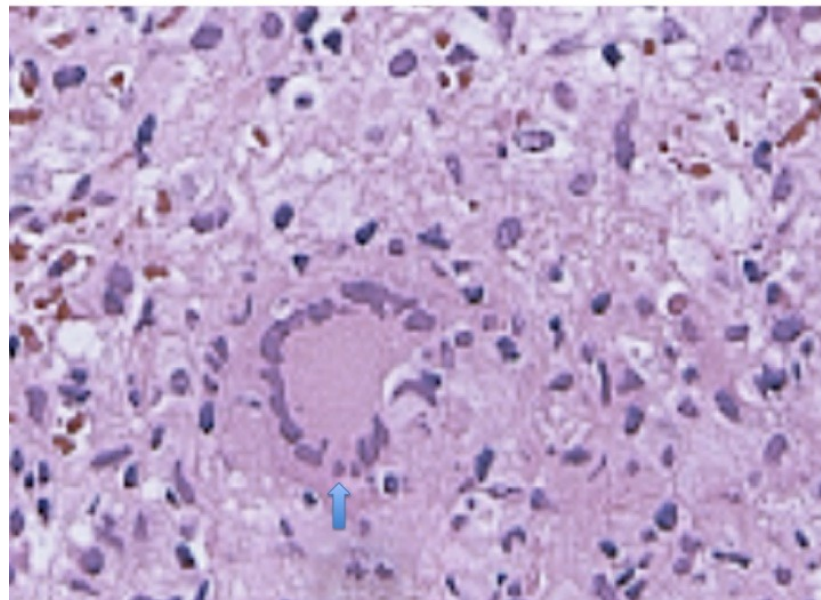


Figure 4: Hepatic histopathology of patient showing granuloma

biopsy of the liver was scheduled in order to rule out malignancy and to have a complete diagnosis. Cytology demonstrated a tuberculosis granuloma, acid-fast bacilli culture was positive (figure 4). Anti-tuberculous therapy including isoniazid, rifampin, ethambutol, and pyrazinamide were prescribed. The patient completed the 6-month course of medication with success. The patient's appetite and body weight were restored to previous levels. One year after the completion of

treatment, the patient remained completely asymptomatic with disease free.

Discussion

Tuberculosis is a health problem in the developing countries [1]. It remains a healthcare challenge in the developed world probably due to increased immigration as well as to an increase in patients with the acquired immunodeficiency syndrome (AIDS) [2]. Since 1950, 21 cases of isolated tuberculoma or tuberculous abscess

of the liver have been reported in the world literature. Abdominal tuberculosis is a rare manifestation of extrapulmonary forms. Hepatobiliary tuberculosis is rare [3]. Usually it is associated with foci of infection in the lungs or gastrointestinal tract [4].

Diffuse hepatic involvement with pulmonary or miliary tuberculosis is the most frequent forms in hepatic tuberculosis. The second common form is granulomatous hepatitis. It is a diffuse hepatic infiltration without pulmonary involvement. In our patient the lesion was a pseudotumor of the liver and presents the third form as a focal local tuberculoma or abscess [5].

Tuberculosis spreads to the liver through the hepatic artery, the portal system and the lymphatic system. It commonly involves the hepatic parenchyma and sometimes the biliary tree [4,6]. Both caseating and non-caseating granulomas were described. Focal tuberculosis appears as nodules with calcifications. These nodules are sometimes the source of hematogenic spread [6,7]. The diagnosis can be easy if all criteria established by Maharaj et al are found such as hepatic granuloma with or without Langhans-type giant cells, and/or caseation plus tubercle bacilli elsewhere [8]. A previous history of tuberculosis infection should help for the diagnosis. Pseudotumor liver is an uncommon manifestation of hepatic tuberculosis. The clinical presentation is not specific and a high degree of clinical suspicion is required to diagnose the entity [9]. The most common symptoms are right upper quadrant pain, fever, anorexia, and weight loss. The clinical features of local form hepatic tuberculosis are variable. Hepatomegaly and splenomegaly are common and liver is often tender and nodular [4,9]. Although liver function tests were normal

in our case, abnormal Liver Function Tests may be present. Anemia and elevated erythrocyte sedimentation rate are often seen [10].

Imaging is useful for diagnosis. Abnormal chest x-rays demonstrating pulmonary tuberculosis can help for diagnosis. Our patient presented with no evidence of active pulmonary disease and the ultrasonography showed a hypoechoic rim and solitary lesion. In these cases, it is difficult to differentiate them from carcinoma [11].

Computed tomography (CT) and magnetic resonance imaging (MRI) are helpful in diagnosis.

CT findings of tuberculosis abscesses can show low-density focal lesions with or without ring enhancement on contrast administration. These have also been seen in necrotic tumor such as hepatocellular, inflammatory disease and metastatic carcinoma [12].

CT-guided aspiration and biopsy can confirm the diagnosis. Percutaneous needle biopsy of the liver using ultrasound, CT has greater than 90 percent sensitivity. In case of pseudotumor tuberculosis mimicking a carcinoma, the role of biopsy is important because it can change therapeutic attitudes. The definitive diagnosis of this disease is conventionally made by histological analysis of caseating granuloma or demonstration of acid-fast bacilli on culture of biopsy specimen [13].

Otherwise, the rate of accurate pretreatment diagnosis by guided percutaneous liver biopsy has been reported to be low, and the presence of tubercle bacilli in the biopsy sample is rare. In these cases, using polymerase chain reaction to directly detect the presence of Mycobacterium tuberculosis improves sensitivity rates [14].

CT drainage is good for the successful drainage of tubercular abscess, although surgical drainage may occasionally be required [15].

The treatment of hepatobiliary tuberculosis does not differ from other extrapulmonary tuberculosis. We usually use Chemotherapy with standard anti-tuberculosis drugs. This is true for both diffuse as well as the local forms of the disease. In general, a 6- to 9-month regimen (2 months of Isoniazid, Rifampin, Pyrazinamide, and Ethambutol followed by 4–7 months of isoniazid and rifampin) is the recommended treatment for extrapulmonary tuberculosis [3,10,16].

The surgical treatment is most often indicated when a diagnosis of liver tumor is assumed. In these cases therapeutic modalities include all kinds of hepatic resection with postoperative administration of antituberculous agents [17].

The prognosis remains excellent with appropriate antibacillous treatment. The Mortality rate for hepatic tuberculosis is higher in immunodeficient patient. Predictive factors of mortality are age under 20 years, miliary tuberculosis, concurrent steroid therapy, AIDS, cachexia, associated cirrhosis and liver failure [10].

Conclusion

Liver tuberculosis is a rare and curable disease. The clinical presentation of isolated liver tuberculosis is non-specific. Preoperative diagnosis when it presents, as pseudotumor lesions are difficult. Histopathology is necessary for diagnosis. Because of the increasing incidence of tuberculosis, clinicians should be aware of the possibility of tuberculosis disease with liver pseudotumor.

Competing Interest: No benefits in any form have been received or will be received from a commercial

party related directly or indirectly to the subject of this article.

References :

1. Kizub D, Ghali I, Sabouni R, Bourkadi JE, Bennani K, El Aouad R, Dooley KE. (2012)Qualitative study of perceived causes of tuberculosis treatment default among health care workers in Morocco. *Int J Tuberc Lung Dis.*16(9):1214-20.
2. Bernabeu Mora R, Paredes Reyes P, Latour Pérez J, Méndez Martínez P, Lorenzo Cruz M, Sánchez Gascón F (2002) Tuberculous liver abscess in an immigrant patient with pulmonary tuberculosis . *Arch Bronconeumol.* 38 (5):246-8
3. Soufi M, Benamer S, Chad B (2011). Pseudotumoral gallbladder tuberculosis. *Rev Med Interne.* 32(3): 32-3
4. Gallinger S, Strasber SM, Marcus HI(1986). Local hepatic tuberculosis, the cause of a painful hepatic mass: case report and review of the literature. *Can J Surg* 29:451–2
5. Spiegel CT, Tuazon CU (1984).Tuberculosis liver abscess. *Tubercle.* 65:127–31.
6. Robert D , Zipser, James E , Rau, Richard R, Ricketts, Lynn C , Bevans .(1976) Tuberculous pseudotumors of the liver .*Am j med* 61 (6) : 946-951
7. Sonika U, Kar P. (2012)Tuberculosis and liver disease: management issues. *Trop Gastroenterol.* 2012 ;33(2):102-6.
8. Maharaj B, Leary W P, Pudifin D J. (1987). A prospective study of hepatic tuberculosis in 41 black patients. *Q J Med* 63: 517-22.
9. Lee SW, Lien HC, Chang CS , (2010).Tuberculous liver abscess in a case without lung involvement.

Kaohsiung J Med Sci. 26 (2):99-104.

10. Chaudhary P. (2014). Hepatobiliary tuberculosis.

Ann Gastroenterol. 27(3):207-211.

11. Cao BS, Li XL, Li N, Wang ZY. (2010). The nodular form of hepatic tuberculosis: contrast-enhanced ultrasonographic findings with pathologic correlation. J Ultrasound Med. 29(6):881-8

12. Yu RS, Zhang SZ, Wu JJ, Li RF. (2004). Imaging diagnosis of 12 patients with hepatic tuberculosis. World J Gastroenterol. 1;10(11):1639-42

13. Lee WK, Van Tonder F, Tartaglia CJ, Dajia C, Cazzato RL, Duddalwar VA, Chang SD. (2012). CT appearances of abdominal tuberculosis. Clin Radiol. 67(6):596-604.

14. Alcantara-Payawal DE, Matsumura M, Shiratori Y, Okudaira T, Gonzalez R, Lopez RA, Sollano JD, Omata M. (1997). Direct detection of Mycobacterium tuberculosis using polymerase chain reaction assay among patients with hepatic granuloma. J Hepatol. 27(4):620-7.

15. Wilde CC, Kuch YK. (1991) Case report : Tuberculous hepatic and splenic abscess. Clin Radiol 43:215-6.

16. Hu ML, Lee CH, Kuo CM, Huang CC, Tai WC, Chang KC, Lee CM, Chuah SK (2008). Liver tuberculosis in Southern Taiwan: 15-years clinical experience. J Intern Med Taiwan. 19:410–417.

17. Xing X1, Li H, Liu WG. Hepatic segmentectomy for treatment of hepatic tuberculous pseudotumor. Hepatobiliary Pancreat Dis Int. 2005 Nov;4(4):565-8.