

Peripheral Third Cranial Nerve Palsy in A Patient With Pediatric Form of Multiple Sclerosis

Najo Jomaa¹, Grace Adwane¹, Abdallah Rahbani^{1,2,*}

¹Department of Neurology, Lebanese University.

²Department of Neurology, Lebanese Hospital University Hospital, Lebanon

Abstract

Multiple Sclerosis has traditionally been considered an inflammatory and autoimmune disease of the central nervous system. However, peripheral cranial nerve involvement has been described previously in eight cases, raising the hypothesis of a disease spectrum between central and peripheral nervous system. We hereby present a case of a 12 years old girl diagnosed with Multiple Sclerosis who presents with complete unilateral third cranial nerve palsy. Complete clinical, laboratory and radiological work-up was consistent with demyelinating disease. We conclude that demyelination in Multiple Sclerosis can affect in some cases both the central and peripheral nervous system.

Research Article
Open Access &
Peer-Reviewed Article

Corresponding author:

Abdallah Rahbani, Department of Neurology, Lebanese Hospital University Hospital, Lebanon.

Keywords:

Sclerosis, central nervous system, peripheral cranial nerve, demyelination, autoimmune demyelinating disease.

Received: March 26, 2024

Accepted: June 14, 2024

Published: June 17, 2024

Academic Editor:

Ashraf Naeem, Zagazig University, Faculty of medicine, Anatomy and Embryology Department, Egypt.

Citation:

Najo Jomaa, Grace Adwane, Abdallah Rahbani (2024) Peripheral Third Cranial Nerve Palsy in A Patient With Pediatric Form of Multiple Sclerosis. International Journal of Multiple Sclerosis and Related Disorders - 1 (1):6-9.

Introduction

It has always been considered that Multiple Sclerosis (MS) is a chronic inflammatory and autoimmune demyelinating disease of the central nervous system (CNS) [1]. However, the involvement of the peripheral nervous system (PNS) has been shown to be associated with MS in different previous studies raising the concept of a possible disease spectrum between PNS and CNS demyelinating diseases [2,10].

It is common to have an involvement of the brainstem at anytime through the course of the disease in MS. These would usually cause many symptoms including ocular motility problems. However, an isolated inflammation of cranial nerves is very rarely reported in MS [2].

Eight cases of an isolated third cranial nerve palsy have been reported in the English language literature. These had a variable range of symptoms regarding ophthalmoplegia, pupil involvement, ptosis and pain. Magnetic resonance imaging (MRI) was done in 6 cases with 4 cases showing a midbrain lesion and only one case showing an enhancement of the third cranial nerve [2-9].

We hereby present a case of an isolated complete third cranial nerve palsy in a patient diagnosed with pediatric MS.

Case Report

A 12 years old girl presented acutely with left eye ptosis. She had a mydriatic left

pupil along with binocular diplopia. She was diagnosed as having a complete left third cranial nerve palsy.

A year prior to this presentation, she was evaluated for blurred vision in her left eye. She had no previous medical problems then, nor did she have any family history of neurological disease. She was diagnosed at that time to have optic neuritis. **Brain and total spine MRI's were done at that time and demonstrated the presence of multiple lesions of demyelinating nature. These lesions were more consistent with Multiple Sclerosis. Visually evoked potentials and Somatosensory evoked potentials were also abnormal. Anti-Aquaporin 4 along and all the autoimmune work-up were negative. Lumbar puncture done at that time showed a high IgG index and the presence of oligoclonal bands.** The patient received high doses of methylprednisolone intravenously with total resolution of the symptoms.

She was followed with brain and spine MRIs over several months after which she was considered to have a pediatric form of Multiple Sclerosis. For this reason she was started on weekly intramuscular injections of interferon Beta 1a.

She was doing very well on treatment, until this presentation, when she presented acutely with left third cranial nerve palsy. Due to this atypical presentation MRI with MR angiogram (MRA) of the brain were performed with additional thin cuts over the exit of the third cranial nerve and showed no evidence of any aneurismal lesion or a mass lesion. However, there was an increase in the size of a previously present left midbrain lesion [See Figure 1].

This was considered as being a rare and very atypical presentation of multiple sclerosis and the patient received a course of steroids with full recovery within 4 weeks.

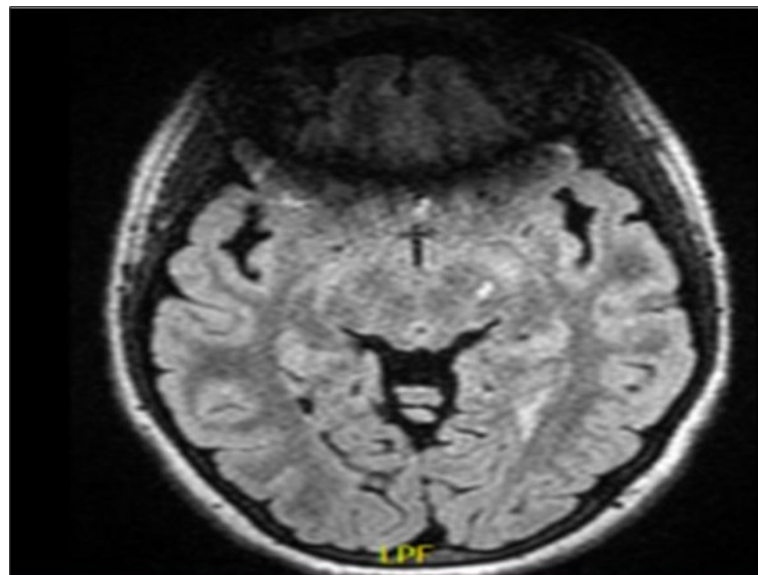


Figure 1. showing a left midbrain demyelinating lesion on a fluid attenuated inversion recovery (FLAIR) image. To note, there is an artifact anteriorly because of the presence of teeth orthodontics.

Discussion

The above mentioned case supports previous case reports that showed a cranial nerve involvement in MS. It has been shown, for example, in a review of 1278 cases of third, fourth and sixth cranial nerve palsies that 40 cases had MS. This is in addition to the 8 cases reports of an associated MS with a third cranial nerve palsy.

These rare cases of an associated peripheral and central nervous system involvement in MS suggest a possible common target for immune response between CNS and PNS in this subset of patients.

On the other hand, some studies showed a central nervous system involvement in patients having an inflammatory demyelinating polyneuropathy [2].

This would also raise the question about molecular similarities between the targets of immune cell response in MS and peripheral neuropathies, i.e. between the central and the peripheral nervous system myelin.

Conclusion

Peripheral nervous system involvement in MS is a very rare occurrence that should be recognized and investigated further for the underlying pathophysiology. This would highlight the question of whether it would be considered a distinct disease entity involving both peripheral and central nervous systems myelin.

Declaration of Conflict of Interest

The author(s) declared no conflicts of interest associated with this publication.

Funding

The author(s) disclosed no financial support for this publication.

References

1. Kalman B, Lublin FD. Spectrum and classification of inflammatory demyelinating diseases of the central nervous system. *Curr Neurol Neurosci Rep* 2001; 1:249-256.
2. M. Tariq Bhatti et al. Peripheral Third Cranial Nerve Enhancement in Multiple Sclerosis. *Am J Neuroradiol* 2003; 24: 1390-1395.
3. Dessai HB, Macfadyen DJ. Multiple sclerosis presenting as third nerve palsy. *Can J Neurol Sci* 1987; 14: 178-179.
4. Uitti RJ, Rajput AH. Multiple Sclerosis presenting as isolated oculomotor nerve palsy. *Can J Neurol Sci* 1986; 13: 270-272.
5. Galer BS, Lipton RB, Weinstein S, et al. Apoplectic headache and oculomotor nerve palsy: an unusual presentation of multiple sclerosis. *Neurology* 1990; 40:1465-1466.
6. ksaizek SM, et. Divisional oculomotor nerve paresis caused by intrinsic brainstem disease. *Ann Neurol* 1989; 26:714-718.
7. Bentley PI, Kimber T, et al. Painful third nerve palsy in MS. *Neurology* 2002; 58:1532.
8. Lee AG, Tang RA, et al. Isolated inferior rectus muscle palsy resulting from a nuclear third nerve

- lesion as the initial manifestation of multiple sclerosis. *J Neuroophthalmol* 2000; 20: 246-247.
9. Newman NJ, Lessel S. Isolated pupil-sparing third-nerve palsy as the presenting sign of multiple sclerosis. *Arch Neurol* 1990; 817-818.
 10. Goldenberg MM. Multiple sclerosis review. *P T*. 2012;37:175–184.