

Morphological and Functional Abnormalities of the Thyroid Gland among End Stage Kidney Disease Patients

Osman, O.¹, Alnaemi, T.², Alneel, S.³, Qayyum, F.⁴, Abdalla, M.⁵, Makeen, A.⁶, Griffith, B.⁷

1. Consultant nephrologist, Alqunfudah Hospital, KSA.
2. Radiologist, Alqunfudah Hospital, KSA.
3. Internal medicine specialist, Alqunfudah Hospital, KSA.
4. Nephrology resident, Alqunfudah Hospital, KSA.
5. Nephrology resident, Alqunfudah Hospital, KSA.
6. Professor of Medicine and Endocrinology, IUA.
7. Assistant professor of Radiology and Consultant Radiologist, Inova Fairfax Hospital, USA.

Abstract

Several interactions exist between thyroid and kidney function in many disorders. Many publications explored the relationship between thyroid diseases (TD) and chronic kidney diseases (CKD). However, the morphological thyroid changes in patients with CKD or End Stage Kidney Disease (ESKD) were not fully explored. The aim of this study is to explore the morphological and the functional abnormalities of the thyroid gland among ESKD patients as detected by Doppler ultrasound.

Patients and methods: All of the 92 ESKD patients at our center were consented and included in the study. Demographic and clinical data and biochemical and hormonal profiles were recorded. Every patient received a dedicated ultrasound scan of the thyroid gland. GE ultrasound system with Doppler capabilities and high frequency transducer was used. Grey scale imaging and Doppler ultrasound were used to image the thyroid gland for every patient. Taking the thyroid morphology detected by ultrasound and the thyroid function as the dependent variables, all other parameters of age, sex, BMI, occupation, residence, duration of time on dialysis and other comorbidities were taken as independent variables and their relationship to the dependent variables was further studied using appropriate statistical tests.

Results: Thyroid nodule(s) presence was found to be the most prevalent thyroid morphology detected on ultrasound scanning. Fifty three patients (57.6%) were found to have ultrasound detected nodule(s). The nodule presence was correlated to different independent variables and was found to significantly correlate with age only. The thyroid function as reflected by the level of thyroid hormones was also studied for correlation with the independent variables. No correlation was found between the thyroid function and the presence of nodules.

Conclusion and recommendation: Ultrasound detected nodules are very common in ESKD patients. The presence of nodule significantly correlates with patient age denoting its degenerative nature. Ultrasound screening of the thyroid in ESKD patients may be cost effective. However, we recommend a larger multicenter study for better results.

Corresponding author: Osman O, Consultant nephrologist, Alqunfudah Hospital, KSA

Citation: Osman O, Alnaemi T, Alneel S, Qayyum F, Abdalla M et al. (2017) Morphological and Functional Abnormalities of the Thyroid Gland among End Stage Kidney Disease Patients. Journal of Hematology and Oncology Research - 2(4):24-32. <https://doi.org/10.14302/issn.2372-6601.jhor-17-1606>

Editor: Krzysztof Roszkowski, Department of Oncology F. Lukaszczyk Oncology Center Nicolaus Copernicus University

Keywords: Thyroid Gland, ESKD, Ultrasound Imaging`

Received: May 26 2017

Accepted: June 26 2017

Published: Aug 08 2017

Introduction:

As reported in the literature, there are several interactions between thyroid and kidney function in many disorders [1]. Basu et al reported that hypothyroidism is associated with reduced Glomerular filtration rate (GFR) while hyperthyroidism results in increased GFR as well as increased rennin -aldosterone axis activation. They also added that chronic kidney disease (CKD) may be associated with low T3 syndrome [1]. CKD patients are also reported to have increased incidence of primary hypothyroidism and subclinical hypothyroidism [2].

Ultrasound imaging of the normal thyroid:

The normal thyroid gland consists of two lobes connected with an isthmus [3]. The major limitation of ultrasound in thyroid imaging is that it cannot determine thyroid function, i.e. whether the thyroid gland is underactive, overactive or normal in function; for which a blood test or radioactive isotope uptake test is generally required[4],[5]. However, when Doppler US is used, increased gland vascularity may often indicate hyperthyroidism.

Thyroid ultrasound examination technique:

The thyroid gland is examined with neck hyperextended using a high frequency ultrasound transducer, usually in the range of 7-12 MHz, for better resolution. Real time imaging of the thyroid is obtained using both gray-scale and color Doppler techniques. The image characteristics e.g. size, shape, margins, echogenicity, contents and vascular pattern are studied and documented [6], [7].

Normal thyroid gland:

The superficial location of the thyroid gland renders it ideal for ultrasound examination [8]. High resolution grey scale images can easily be obtained using high frequency transducer. In the transverse view, normal thyroid gland has the butterfly appearance, with left and right lobes connected with a narrow isthmus, fig (1A). Both lobes can be imaged separately in the longitudinal plan, Fig (1B)

Normal thyroid Volume:

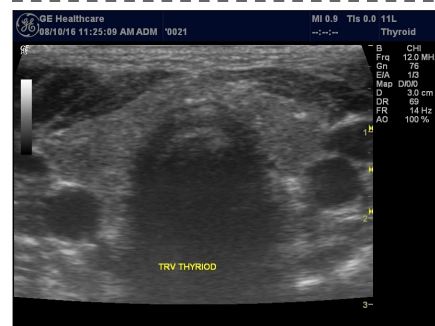
Normal thyroid volume ranges from 10-15 ml in women and 12-18 ml in men [9]. In children the thyroid volume, varies with age [10].

Color Doppler may be used to study the blood flow pattern of the thyroid gland, Fig (2). Thyroid blood flow may increase in some thyroid disorders like Graves' disease.

Abnormal thyroid scan:

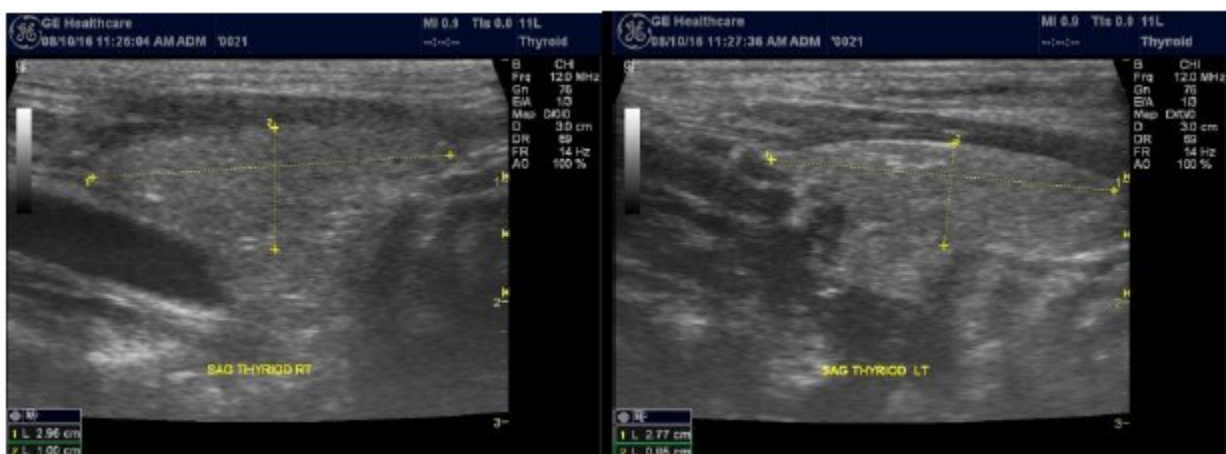
Many thyroid abnormalities can be detected by

Figure (1A). Normal thyroid gland transverse view:



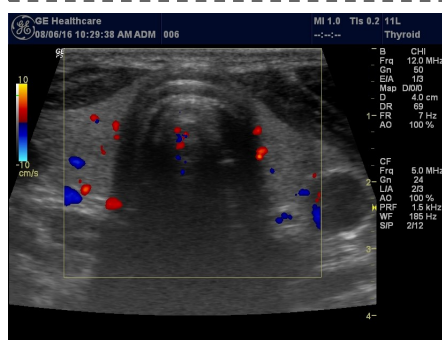
ultrasound. Thyroid pathology detectable by ultrasound can be grouped into focal and diffuse. Thyroid nodules

Figure 1B. Normal thyroid gland long view:



are the most common focal thyroid pathology [11]. Diffuse Thyroid pathology includes diffuse of thyroid enlargement as seen in Hashimoto's (lymphocytic) thyroiditis, de-Quervain's subacute thyroiditis, multinodular goiter and Graves' disease [3]. The ultrasonographic features of these pathological entities may be similar but they demonstrate different biochemical and clinical profiles. Accordingly, ultrasound findings should be viewed in the biochemical and clinical context [3].

Figure (2). Blood flow pattern in normal thyroid gland:



objective, all the 92 chronic hemodialysis patients at Prince Sultan Kidney Dialysis Center at Alqunfudah general hospital were consented and included in the study. All patients underwent thyroid ultrasound scanning. Grey scale imagings were obtained first followed by Doppler interrogations. GE ultrasound system with high-resolution linear probe (7.5-12 MHz) and advanced scanning techniques like extended field of view and compound harmonic imaging were applied to get the best image quality. Demographic and clinical data were recorded for all patients in addition to chemical and hormonal laboratory results. The collected data was processed and analyzed to satisfy the objectives of the study. The categorical data was presented as frequency and percent. The continuous data was presented in terms of mean and standard deviation. χ^2 test was used for categorical data, student t-test was used for continuous data. To better study the relationship between the dependant and the independent variables, logistic regression was used to study all the possible directions of the association between the dependant and the independent variables.

Results:

The sample population is composed of 50 (54.3%) male and 42 (45.7%) female mirror image the male dominance of kidneys diseases, table (1). The age of the participants falls in the range of 15-85 years with a mean of 54.6 years and a median of 60 years denoting the degenerative nature of ESKD with incidence increases with age. Table (2).

The presence of nodule(s) was found to be the most common morphology detected by ultrasound among the study cohort, table (3).

The mean age of those with nodules is higher (59.66 years) than the mean age of those without nodules (47.68 years). The differences was found to be statistically significant ($P = 0.001$) denoting also the degenerative nature of thyroid nodules, table (3).

When the relationship between the presences of nodule is studied versus the other demographic variables (age, sex, height, weight, BMI, occupation, family size and residency), it was found to significantly correlate with age ($P = 0.024$). No significant correlation was found between the presence of nodule and other demographic variables. In contrary to the fact that thyroid diseases are more common in female, no significant variation in nodules presence was found with sex.

Thyroid function derangement in ESKD patients:

Depending on the GFR, CKD is divided into five stages. The final stages is known as the End Stage Kidney Disease (ESKD) at which the patient will require renal replacement therapy to sustain life. A disturbance of thyroid function is common in ESRD (End Stage Renal Disease) [12].

Many publications focused on the relationship of thyroid diseases (TD) and CKD. Victoria etal [2] published in 1977 about thyroid dysfunction in chronic renal failure. Then in 2014 Mohamedali etal [13] published about the thyroid disorders and chronic kidney disease. Between Victoria and Mohamedali many publications came out exploring the Interactions between TD and CKD. The example of these publications is given by what have been published by Lim VS in 2001[14]; P Iglesias etal in 2009[15] and Gopal Basu etal in 2012[1]. However, most published data dealt mainly with the functional relationship between TD and CKD; in this study the morphological abnormalities of thyroid among ESKD as detected by Doppler ultrasound imaging were also explored.

Patients and Methods:

The main objective of this study is to examine the morphological and functional abnormalities of the thyroid gland among ESKD Patients. To achieve this

Also no significant correlation was found between the presence of nodule and other comorbidities (diabetes, hypertension and other comorbidities) or between the presence of nodule and the duration of time on dialysis in months.

The presence of a thyroid nodule significantly correlated with CRP (P=0.014) when t- Test was used. However, when this relation was further scrutinized using logistic regression, it was not found significant. No significant correlation was found between the presence of nodule and other biochemical parameters (ESR, Phosphate, Calcium, ALP and thyroid and parathyroid hormones), table (4). The relationship between the nodule presence and the virus status of the participants was also studied but no significant correlation was found, table (5).

1. Also no significant difference was found in the presence of thyroid nodule among those who reported

Table 1. shows the gender percentage of the patients:

Cumulative Percent	Valid Percent	Percent	Frequency	
54.3	54.3	54.3	50	male
100	45.7	45.7	42	Female
	100	100	92	Total

thyroid disease symptoms and/or signs and those who

Table 2. shows the Age and BMI of the patients:

BMI	HEIGHT	WEIGHT	AGE	
91	91	91	91	Valid
1	1	1	1	Missing
22.4109	156.18	55.236	54.62	Mean
21.5188	156	55	60	Median
5.55904	12.382	16.5624	16.475	Std. Deviation
12.86	110	18.5	15	Minimum
42.24	185	115	85	Maximum

did not.

Discussion:

The reported prevalence of nodular thyroid

Table 3. shows that the presence of nodule(s) significantly increases with age:

Std. Error Mean	Std. Deviation	Mean age	N	Nodule
2.099	15.281	59.66	53	Nodule present
2.714	15.828	47.68	34	No nodule

disease depends on the population studied and the methods used to detect nodules [16]. Our study population is unique as it is composed entirely of ESKD

patients. We also used ultrasound as a method of detecting thyroid abnormalities. In our study the prevalence of thyroid nodular pathology as detected by ultrasound was found to be 57.6% mirror image what reported in the literature as it has been reported that nodules found on ultrasonography suggest a prevalence of 19 to 67%[17], [18]; and in other publications it has been reported to range from 50% to 70% [7,8]. Figure (3A) below shows an ultrasound detected thyroid nodule.

The prevalence of thyroid nodule is also influenced by age. In one study, 30 % of subjects 19 to 50 years of age had an incidental nodule on ultrasonography[19]. However, from our work we found that the presence of nodules increases with age. This may explain the reported low incidence of thyroid nodule in the age group 19-50 years. Also, with the widespread use of sensitive imaging in clinical practice, incidental thyroid nodules are being discovered with increasing frequency.

High-resolution ultrasonography (USG) is the most accurate and cost-effective method for evaluating and observing thyroid nodules [3]. Although there is some overlap between ultrasound appearance of benign and malignant nodules, certain USG features are helpful in differentiating the two. Iso- or hyper-echogenicity of the thyroid nodule in conjunction with a spongiform appearance is the most reliable criterion for benignity of the nodule on gray-scale ultrasound, figure (4A). Other features like nodule size <1 cm, width > length, presence of hypoechoic or hyperechoic halo around the nodule, figure (4A) and figure (4B), caused by fibrous capsule compressing thyroid tissue, and coarse/curvilinear calcification are less specific but may be useful ancillary signs[4] , [6]. "Ring down" or "comet-tail" artifact or sign is typical of benign cystic colloid nodule, figure (5) [20]. Perinodular flow or spoke-and-wheel-like appearance of vessels on color Doppler examination is characteristic of a benign thyroid nodule. However, this flow pattern may also be seen in thyroid malignancy. A complete avascular nodule is very unlikely to be malignant [4].

Malignant focal thyroid pathology: Thyroid cancer is classified according to the histological appearance into papillary carcinoma (60-80%), follicular carcinoma (20-25%), medullary carcinoma (4-5%), anaplastic carcinoma (3-10%), lymphoma (5%) and

Table 4. Shows the Biochemical and hormonal variations of the patients:

	CA	PHOSPH	PTH	ALP	T3	T4	ESR	CRP
Valid	91	91	91	89	87	87	77	81
Missing	1	1	1	3	5	5	15	11
Mean	7.944	4.788	832.76	168.8	4.3983	11.662	58.9	8.59
Median	8.1	4.7	628	102	4.28	11.59	60	6
Std. Deviation	0.9576	1.6702	809.958	202.956	0.94357	2.4485	38.757	5.995
Minimum	5.5	0.9	7	36	2.38	4.8	3	6
Maximum	9.8	10.3	4055	1270	8.5	17.9	138	24

metastases[21]. Thyroid ultrasound is reported to have overall sensitivity of 83.3% in diagnosing a malignant nodule [7]. Ultrasound features predictive of malignant

parathyroid glands, fig (6).

Table 5. shows the hepatitis virus status of the patients:

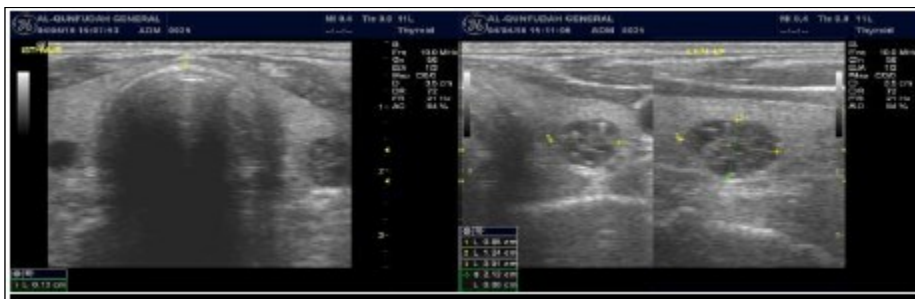
	Frequency	Percent	Valid Percent	Cumulative Percent
Negative	73	79.3	80.2	80.2
C	15	16.3	16.5	96.7
B	3	3.3	3.3	100
Missing	1	1.1		
Total	92	100		

nodules include presence of microcalcifications , marked hypoechoogenicity, irregular margins, local invasion, lymph node metastases, solid composition, absence of a hypoechoic halo around the nodule, size >1 cm, taller-than-wide-shape, and an intra nodular vascularity [22]. Unlike what is popularly known, multiplicity of the nodule is not an indicator of benignity. The incidence of malignancy is same in solitary nodules as it is in multiple

Some experts prefer partial or total thyroidectomy if the cancer is already confirmed before surgery. However, no consensus exists about partial thyroidectomy [23]. Some authors recommend ablation using radioactive iodine (I-131) for high-risk patients with postoperative thyroid replacement therapy but the benefits of administration remain controversial in low-risk patients [23], [24]. Follow up with regular TSH is recommended following complete resection of thyroid cancer. The TSH concentration should be in the target range of 0.5 µU per mL. Greater suppression may be necessary for high-risk patients and those with a metastatic or locally invasive tumor.

In our study we also found that nodule presence significantly increases with age (P. Value .024) going along with what is been published by Vikas Chaudhary, et al [3]. He reported that" Nodule incidence increases with age, and is increased in women, in people with

Figure 3 A. Thyroid nodule:



nodules [3].

Any nodule with intermediate indeterminate cytology or higher on FNA should go to surgery [23]. Among our patients population, one patient with nodular pathology and tertiary hyperparathyroidism was found to have papillary carcinoma of the thyroid during parathyroidectomy. Total thyroidectomy was done and the patient got forearm implantation of one of the

iodine deficiency, and after radiation exposure". However, in our study we could not detect any significant relations with other variables like sex, and Phosphate. We found that CRP significantly correlates with nodule using t-test but not when logistic regression analysis was used. Should the correlation proven to be significant; it would not be difficult to

explain it in light of the fact that inflammation may potentiate degeneration. However, dedicated study to address the issue is needed.

Parathyroid glands pathology:

In our study many patients were found to have nodules look very much like PT adenoma, Fig (7) below. At least, 4 patients were subsequently confirmed to have

parathyroid adenomas, fig (8) and 2 patients underwent surgery

Despite the fact that nodular pathology was

Figure 4A. isoechoic nodule :

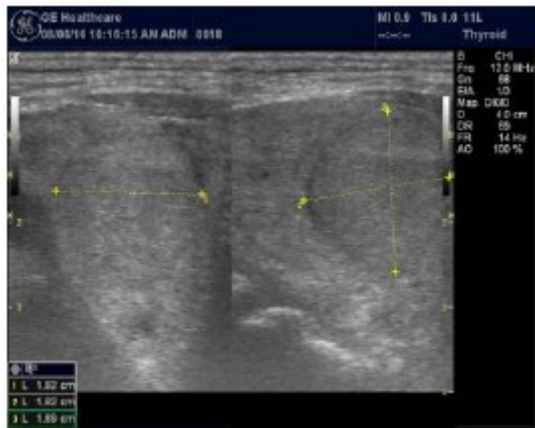

Figure 4B. Isoechoic nodule with Hyperechoic rim:

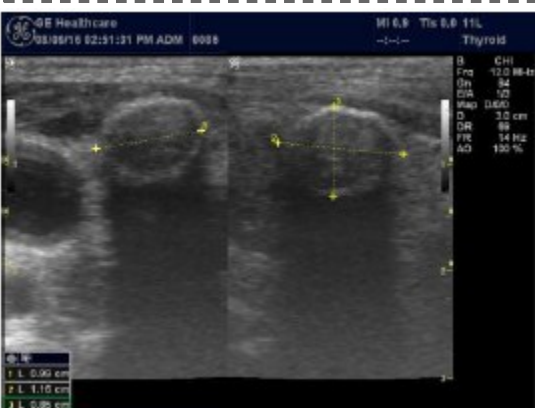
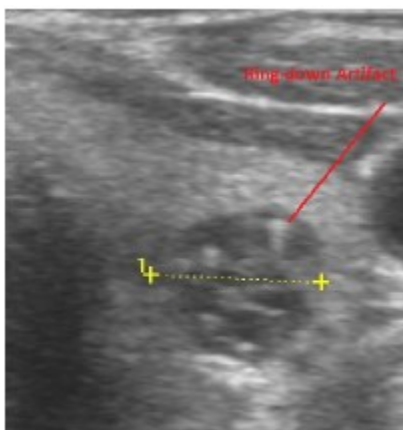


Figure 5. Ring down artifact of colloid nodule:



found to be very prevalent among our study population, it has been found difficult to differentiate between thyroid and parathyroid pathology using ultrasound

alone. However, some characteristics of the parathyroid glands might suggest parathyroid pathology in the context of the clinical picture of secondary or tertiary hyperparathyroidism which is very prevalent in ESKD patients' populations.

There are 4 parathyroid glands (2 superior, 2 inferior) imbedded within the thyroid gland. The parathyroid glands are bean-like shape and small (20-40 mg) [25]. Sonographically, the parathyroid glands have the following features [25]:

- Normal glands: indistinguishable from thyroid parenchyma.
- Hyperplastic glands: hypoechoic, volume <500 mm³.
- Nodular glands: hypoechoic. Volume >500 mm³

Histologically, if the excised gland has volume <500 mm³ it is said to be hyperplastic and if the volume is more than 500 mm³ it is nodular hyperplasia in 80% of cases[26]. In secondary HPT, the increase in the volume of parathyroid glands is associated with increase in vascularity, as evident in Color Doppler imaging [27].

Conclusion:

Despite the fact that nodular pathology of the thyroid is prevalent among ESKD patients, the prevalence was not different from what reported for the general population. Ultrasound imaging is cost effective in detecting nodular thyroid pathology.

However, ultrasound will not differentiate between thyroid and parathyroid pathology. It is also limited in differentiating benign from malignant pathology. These limitations may be overcome by adding Sestamibi parathyroid scan and FNA, respectively.

Recommendations:

We recommend all ESKD patients on dialysis to have annual thyroid ultrasound scan. We also recommend a large multicenter study for better results.

References:

1. Gopal Basu and Anjali Mohapatra ; Interactions between thyroid disorders and kidney disease; Indian J Endocrinol Metab. 2012 Mar-Apr; 16(2): 204–213.
2. Victoria Sy Lim et al; Thyroid Dysfunction in Chronic Renal Failure; J Clin Invest. Sep 1977; 60(3): 522–

Figure 6. Total thyroidectomy and forearm implantation of the parathyroid gland:

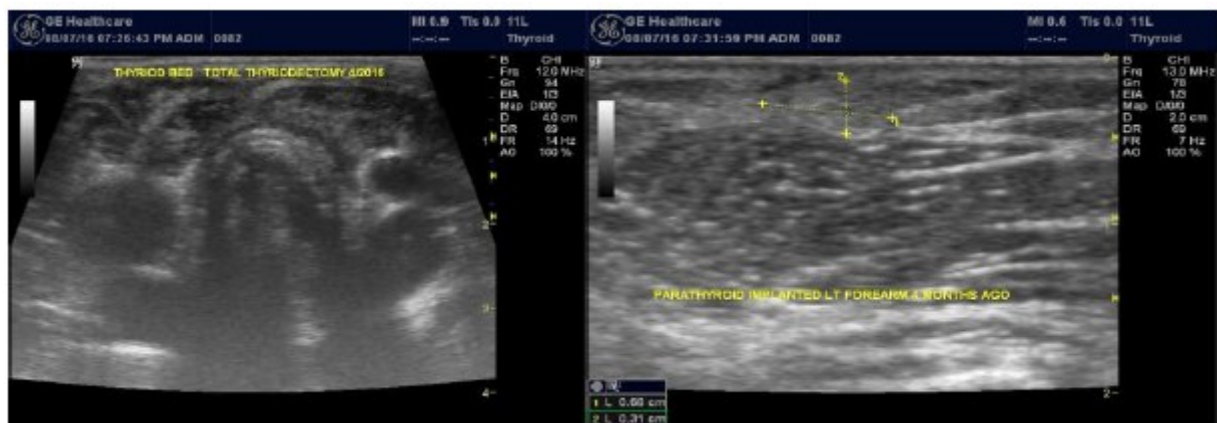
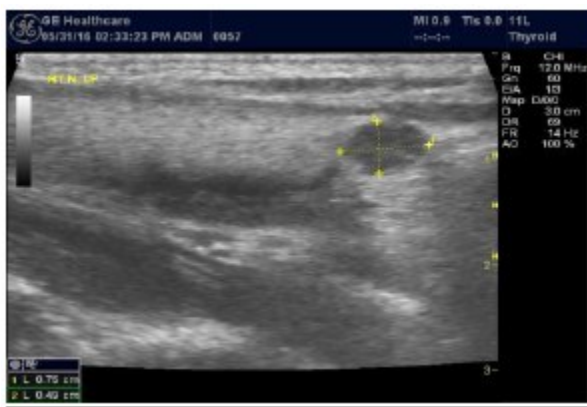


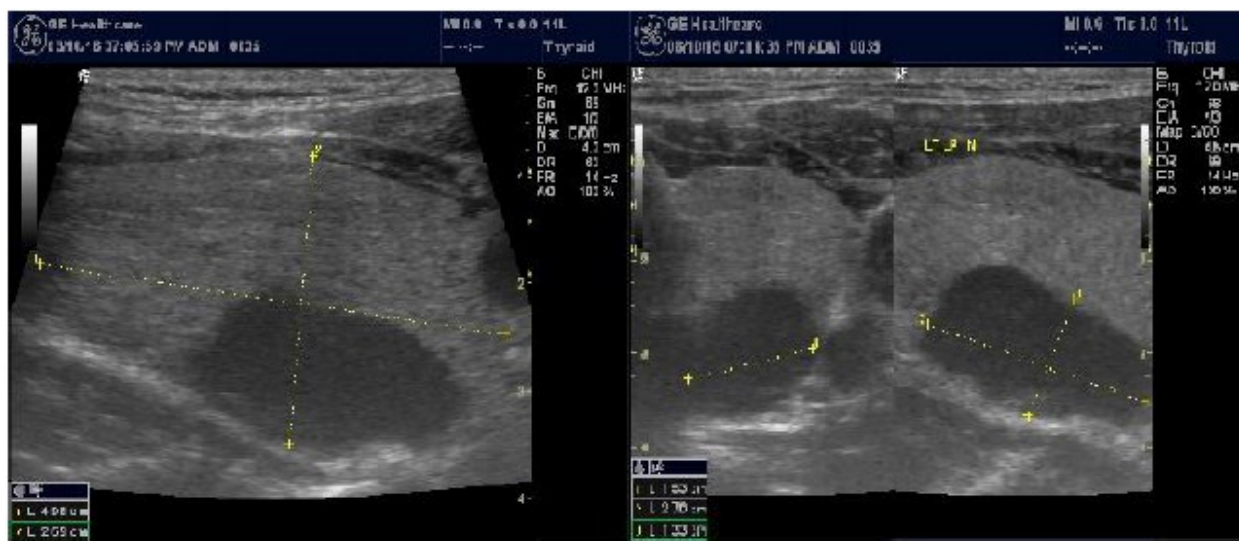
Figure 7. Thyroid nodule suspicious for Parathyroid adenoma due to its location:



534.

3. Chaudhary V, Bano S. Thyroid ultrasound. *Indian J Endocr Metab* 2013;17:219-27.
4. Solbiati L, Charboneau JW, Osti V, James EM, Hay ID. The thyroid gland. In: Rumack CM, Wilson SR, Charboneau JW, editors. *Diagnostic Ultrasound*. 3rd ed., Vol. 1. St. Louis, Missouri: Elsevier Mosby; 2005. p. 735-70.
5. Chaudhary V, Bano S. Imaging of the thyroid: Recent advances. *Indian J Endocrinol Metab* 2012;16:371-6.
6. Baskin HJ. Ultrasound of thyroid nodules. In: Baskin HJ, editor. *Thyroid Ultrasound and Ultrasound-guided FNA Biopsy*. Boston: Kluwer Academic Publisher; 2007. p. 71-86.
7. Moon WJ, Jung SL, Lee JH, Na DG, Baek JH, Lee YH, et al. Benign and malignant thyroid nodules: US differentiation—multicenter retrospective study. *Radiology* 2008;247:762-70.
8. Katarzyna Dobruch-Sobczak, Maciej Jędrzejowski, Wiesław Jakubowski, Anna Trzebińska⁴; Errors and mistakes in ultrasound diagnostics of the thyroid gland; *J Ultrason*. 2014 Mar; 14(56): 61–73. Published online 2014 Mar 30. doi: 10.15557/JoU.2014.0006.
9. Ghervan C. Thyroid and parathyroid ultrasound. *Med Ultrason* 2011;13:80-4
10. Delange F, Benker G, Caron P, et al. Thyroid volume and urinary iodine in European schoolchildren: standardization of values for assessment of iodine deficiency. *Eur J Endocrinol* 1997; 136: 180-187.
11. Ruchała M, Szczepanek E.; Thyroid ultrasound—a piece of cake? *Endokrynol Pol* 2010;61:330-44
12. Sarvghadi Fa, Khalili Sa, Tara Ab, Najafi Jc, Aliasgari Aa, Kolahi ASd; Thyroid Function and Volume Changes in Patients E with End Stage Renal Disease, Before and After Kidney Transplantation; *Int J Endocrinol Metab* 2007; 3: 141-148.
13. Mohamed Mohamedali, Srikanth Reddy Maddika, Anix Vyas, Viswanathan Iyer, and Pramil Cheriya; Thyroid Disorders and Chronic Kidney Disease; *International Journal of Nephrology Volume 2014 (2014), Article ID 520281, 6 pages*
14. Lim VS; Thyroid function in patients with chronic renal failure; *Am J Kidney Dis*. 2001 Oct;38(4 Suppl 1):S80-4.
15. Iglesias, P., Díez, J.; Thyroid dysfunction and kidney disease; *Eur J Endocrinol* April 1, 2009 160 503-515.
16. Dean DS, Gharib H. Epidemiology of thyroid nodules. *Best Pract Res Clin Endocrinol Metab*. 2008 Dec;22 (6):901-11. doi: 10.1016/j.beem.2008.09.019.

Figure 8. Nodule that proven to be a parathyroid adenoma, volume =5265 mm³:



17. Mazzaferri EL. Management of a solitary thyroid nodule. *N Engl J Med* 1993;328:553-9.
18. Tan GH, Gharib H. Thyroid incidentalomas: management approaches to nonpalpable nodules discovered incidentally on thyroid imaging. *Ann Intern Med* 1997;126:226-31.
19. Brander A, Viikinkoski P, Nickels J, Kivisaari L. Thyroid gland: US screening in a random adult population. *Radiology* 1991;181:683-7.
20. Ahuja A, Chick W, King W, Metreweli C. Clinical significance of the comet tail artifact in thyroid ultrasound. *J Clin Ultrasound* 1996;24:129-33.
21. Brkljacic B, Cuk V, Tomiac-Brzac H, Bence-Zigman Z, Deliac-Brkljacic D, Drinkovic I. Ultrasonic evaluation of benign and malignant nodules in echographically multinodular thyroids. *J Clin Ultrasound* 1994;22:71-6.
22. Hoang JK, Lee WK, Lee M, Johnson D, Farrell S. US Features of thyroid malignancy: Pearls and pitfalls. *Radiographics* 2007;27:847-60.
23. Saha AR. Controversies in the management of thyroid nodule. *Laryngoscope* 2000;110(2 Pt 1): 183-93.
24. Singer PA, Cooper DS, Daniels GH, Ladenson PW, Greenspan FS, Levy EG, et al. Treatment guidelines for patients with thyroid nodules and well-differentiated thyroid cancer. *Arch Intern Med* 1996; 156:2165-72.
25. Meola, Mario; Petrucci, Ilaria; Cupisti, Adamasco. Ultrasound in clinical setting of secondary Hyperparathyroidism. *JNEPHROL* 2013; 26(5): 848-855.
26. Périé S, Fessi H, Tassart M, et al. Usefulness of combination of high-resolution ultrasonography and dual-phase dual-isotope iodine 123/technetium Tc 99m sestamibi scintigraphy for the preoperative localization of hyperplastic parathyroid glands in renal hyperparathyroidism. *Am J Kidney Dis.* 2005;45(2):344-352.
27. Martins P, Schmitt F, Almeida H, Frazão JM. Evaluation of parathyroid gland angiogenesis in chronic kidney disease associated with secondary hyperparathyroidism. *Nephrol Dial Transplant.* 2008;23(9):2889-2894.